

# Digital manufacturing of occlusal splint: from intraoral scanning to 3D printing

➤ **P. VENEZIA<sup>1</sup>, L. LO MUZIO<sup>2</sup>, C. DE FURIA<sup>3</sup>, F. TORSELLO<sup>4</sup>**

<sup>1</sup>DDS. Department of Prosthodontics, University of Catania, Catania Italy - Private Practice in Bari, Italy

<sup>2</sup>MD DDS PhD. Department of Clinical and Experimental Medicine, University of Foggia, Foggia, Italy

<sup>3</sup>DMDc. Private Practice in Syracuse, New York, USA

<sup>4</sup>DDS, Ph.D. Department of Periodontology and Prosthodontics, Eastman Dental Hospital, Roma, Italy

## TO CITE THIS ARTICLE

Venezia P, Lo Muzio L, De Furia C, Torsello F. Digital manufacturing of occlusal splint: from intraoral scanning to 3D printing. *J Osseointegr* 2019;11(3):XX

DOI 10.23805 /JO.2019.11.XXX

## ABSTRACT

**Aim** Digital technology has greatly improved its accuracy and precision in the last decade and has allowed for a complete digital workflow in several dental applications. The present paper describes the technique used by the authors for the manufacturing of intraoral occlusal splints featuring a digital workflow.

**Materials and methods** The procedure includes an intraoral scan of the maxillary and mandibular arches, registration of vertical relationship, and computer-assisted design (CAD) technology of the occlusal splint and fabrication with a multi-jet 3D printer.

**Conclusion** The presented technique allows for time efficient laboratory manufacturing, which could also be performed chair-side in the dental office. The delivered splint is accurate and precise and could be reproduced anytime if needed.

**KEYWORD** Intra-oral scanner, 3d printed occlusal appliance, digital dentistry.

## INTRODUCTION

Occlusal splints are widely used in the dental practice for several purposes. They are used as adjunctive treatment of temporomandibular disorders to either relax the muscles or allow the condyle to seat in centric relation and to protect teeth and associated structures during bruxism. Occlusal splints are utilized to provide diagnostic information. Mandibular positions may be tested before proceeding with orthodontic or prosthetic therapies. Lastly, once a complex prosthodontic rehabilitation has been delivered, an occlusal splint will provide additional

protection for patients to wear nocturnally (1-4).

Occlusal splints are generally manufactured with conventional methods, beginning with impressions of the maxillary and mandibular arches to be poured up in stone. The facebow registration is taken to mount the maxillary cast in the articulator. A wax occlusal index is recorded in centric relation with a thickness of few millimeters to mount the mandibular arch. Starting from this recorded relation, the splint is manufactured with the practitioner's material of choice (5).

New technologies have increasingly developed and implemented in the dental field. The introduction of accurate intraoral scanners, CAD/CAM technology, and the increasing diffusion of precise 3D printing machines allow for the digital workflow to manufacture dental prostheses or other intraoral devices (6-11, 13-19). The aim of the present paper is to present a fully digital workflow for the manufacturing of intraoral occlusal splints.

## MATERIALS AND METHODS

The proposed technique for the registration includes the following steps.

- Registration of the correct occlusal relationship for the intraoral occlusal splint with the aid of a wax index.
- Digital impression of the maxillary dental arch.
- Digital impression of the mandibular dental arch.
- Digital scan of the vestibular aspect of the dental arches with the wax index in situ.
- Visualization of the dental arches in the software and control of the quality of the scans.
- Design of the intraoral splint with a CAD software.
- Production of the intraoral splint with a 3D printer.

A clinical case will be used to describe the workflow.

## CASE REPORT

A 55-years old man presented to our office complaining of bilateral facial pain in the masticatory muscles, especially early in the morning, and occlusal instability.

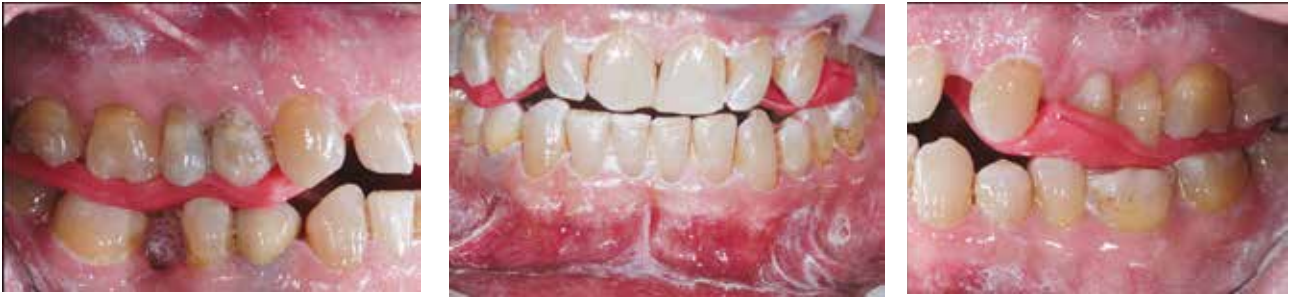

FIG. 1 Patient's intraoral pictures with wax registration taken with the Dawson's bimanual manipulation.

No history of trauma was reported and the clinical examination revealed not significant extra-oral anomalies. Intra-oral examination showed one missing lower molar (4.6) with mesial tipping of teeth 4.7 and 4.8, a porcelain fused-to-metal crown on tooth 4.5 and several tooth reconstructions. Signs of generalized attrition, tooth wear and a mild loss of vertical dimension were also present. Panoramic and periapical radiographs indicated no apical or periodontal active pathologies. The examination of the masticatory system showed no TMJ click or crepitus, but significant bilateral pain upon palpation of the muscles of mastication (anterior portion of temporalis muscles and external pterygoid muscles). The patient complained of a stressful life and admitted that he is subject to clenching and bruxism. It was decided to provide the patient with an intraoral occlusal splint to protect his dentition from continued attrition and provide the mandible with a free repositioning to reduce the hyperactivity of the masticatory muscles before further treatment was completed.

With the accuracy and efficiency of the digital workflow, the splint would be fabricated with digital intraoral scanners and a 3D printer.

### Step 1

The construction of an intraoral occlusal splint should move from the recording of the centric relation position of the mandible, which is a condylar position without occlusal contact between teeth.

The authors used the bimanual manipulation of Dawson

to position the patient's mandible into centric relation (12). A double layer of wax foil was heated at 54°C to create a wax index (Mizzy wax, Keystone Industries GmbH, Germany) leaving enough inter-occlusal space for the splint (2 mm of resin thickness in the posterior areas).

### Step 2 and 3

A digital impression of the maxillary arch was taken recording all the teeth and surrounding structures (master scan). The scanner used for this case (True Definition Scan, 3M, Minnesota, USA) operates with contrast patterning powder in order to increase the speed of the impression, to facilitate data acquisition and its accuracy. Steps 2 and 3: A digital impression of the mandibular arch was then acquired in a second scan.

### Step 4

The wax index previously taken was repositioned and an intraoral scan of the relative position of the two arches was taken on the vestibular aspect. In the bite registration function, the intraoral scanner software is designed to take into consideration only the landmarks needed for this purpose (Fig. 1).

### Step 5

The intraoral scans of the maxillary and the mandibular arches presented enough points in common with the bite registration to have the maxillary and mandibular arches "digitally mounted" with the same intermaxillary relation of the wax index recorded with Dawson's centric relation technique (Fig. 2).

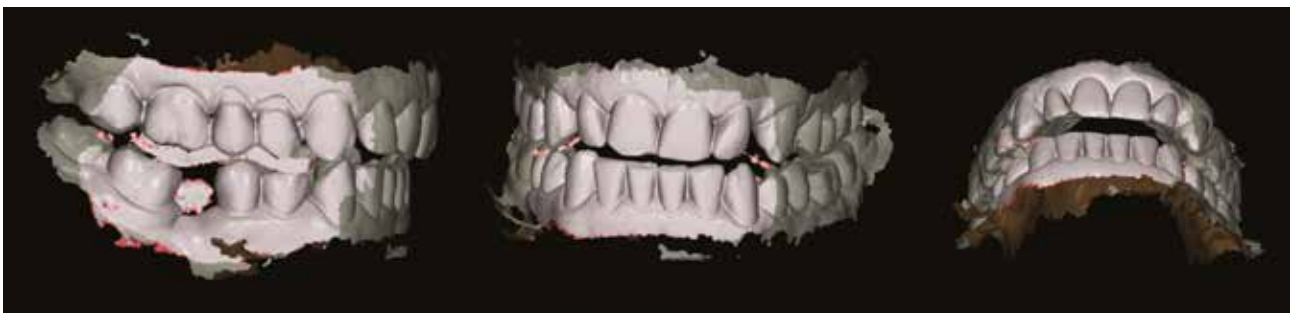

FIG. 2 Intraoral scan with dental arches at the correct vertical relationship as obtained with Dawson's manipulation.

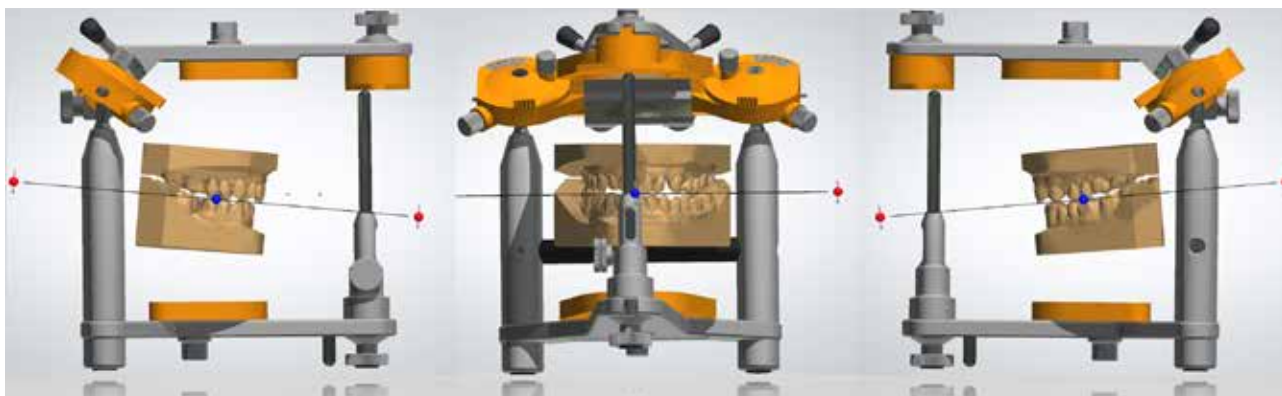


FIG.3 Digital casts in the correct vertical relationship for splint design and manufacturing.

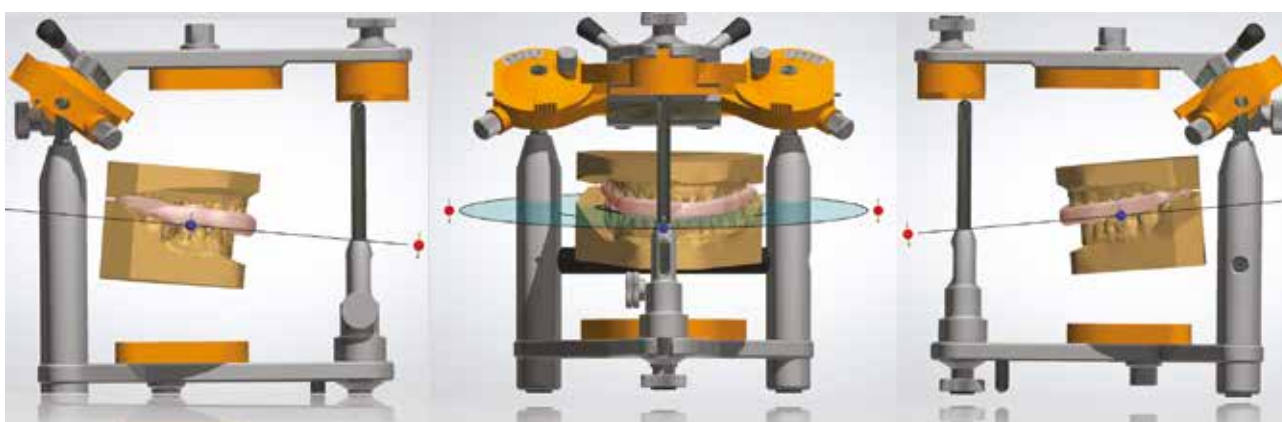


FIG.4 Splint designed on the digital casts.

### Step 6

An STL file was saved from the Intraoral Scanner software and sent to a CAD program (Appliance Designer™, 3Shape A/S, Copenhagen, Denmark), where the digital models were imported to mount on a virtual articulator (Fig. 3).

The initial scan files allowed to relate the lower and the upper virtual models respecting the registration in centric relation and the occlusal rise obtained by the registration wax and which determined the space to be filled up with the appliance.

The initial setting of the virtual articulator provided for the following parameters.

- 40 °TMJ eminence angle.
- 10° Bennet angle.
- 40 ° incisal guide angle.

The bite plane was designed to be retained by the mandibular teeth, according to patient's preference, and the maxillary teeth had a single contact with the appliance (Fig. 4).

### Step 7

The intraoral splint was produced with a 3D printing machine (3D ProJet MJP 3600 Dental, 3D Systems, Rock

Hill, SC, USA) using a multi-jet printing technology and returned to the dental office to be delivered to the patient (Fig. 5). It was made of an organic mixture of acrylic resin produced for dental purposes (VisiJet® M3 Stoneplast, 3D Systems, Rock Hill, SC, USA).

### Step 8

The clinician inserted the intraoral occlusal splint and evaluated the retention and occlusion. Retention was optimal and minimal occlusal adjustments were needed.

Each tooth of the low occlusal appliance. The protrusive and lateral movements were possible in the absence of interferences. The contacts were first tested with 40 micron articulation paper and then with shimstock (8 microns) (Fig. 6). The bite plane was delivered to the patient, who was instructed to wear the splint at night, when at home during the day and in case of pain.

The patient experienced a fast relief of his conditions. His symptoms improved within 3-weeks. Currently, the patient is wearing the occlusal splint during the night for 6 months where his condition has remained asymptomatic and stable.

completare frase

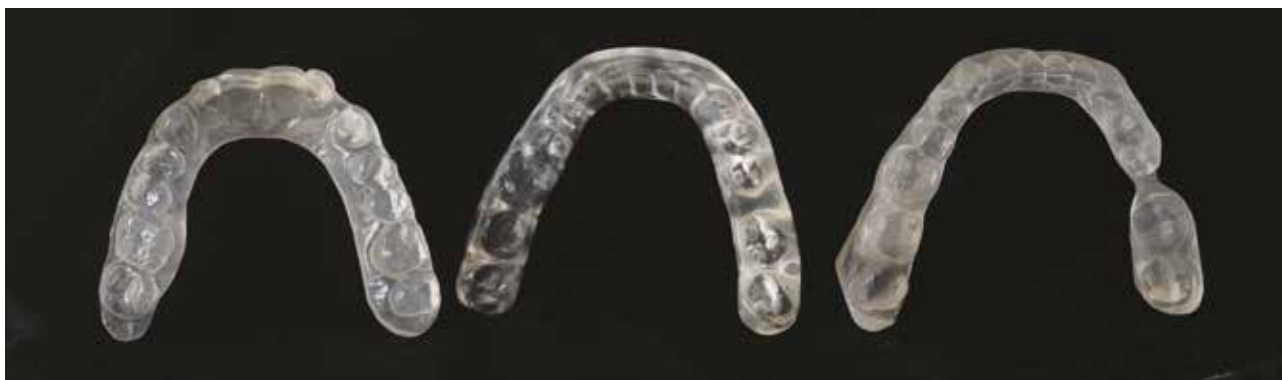

FIG. 5 Splint produced with a multi-jet 3D printer and verified on the prototyped casts.

## DISCUSSION

The digital workflow has provided much advancement for the clinician and the patient for several reasons: the minimally invasive impression technique, the increased time efficiency of recording the bite plane production and the precision of the appliance. Precision could be explained with the accuracy of the intraoral scan as demonstrated by several studies (13-17) and with the 3D precision of the multi-jet printing procedure (18-19). The time spent for this case in the dental office with the digital workflow was similar to the time that would have been spent with a conventional procedure as the intraoral scan took a few minutes less than analog impressions while the delivery of the splint with adaptations close to zero took very little chair-time.

The presented workflow allowed for a noticeable reduction of the complexity and of the total time of the laboratory procedures. Although in this case the authors sent the impression scan to the dental laboratory, the possibility of producing the same appliance in the dental clinic should be considered as 3D printers are becoming more popular within the dental office. However, chair-side production could be time consuming for the dentist and the authors prefer at this time to delegate the design and the production to the dental technician more familiar with CAD software and 3D printers.

An important advantage of the digital workflow is the ability to reproduce, when needed, a replica of the

appliance easily from the CAD project saved as a digital file.

The use of digital technology for the production of intraoral splints has been proposed in the past but mainly for laboratory procedures (20-22). A fully digital workflow has been described for intraoral occlusal splints produced with a milling machine (10). In the presented technique the authors used a fully digital workflow with 3D printers.

The fully digital workflow is frequently used in the dental field, primarily with cases presenting with stable dental relations to restore a single or short span partial edentulisms. In such cases, the relationship between the maxillary and the mandibular arches is usually recorded in maximal intercuspal position. The authors have previously presented an approach to record intermaxillary relations in extended full arch rehabilitations with recorded jaw relations in centric relation (11). A similar approach has been used in the case presented in this paper: the ability to record a centric relation position in a digital approach could be useful in several treatment strategies other than intraoral splint manufacturing, such as increase of vertical dimension which is frequently needed in complex prosthetic cases.

## CONCLUSION

The authors presented a technique to manufacture

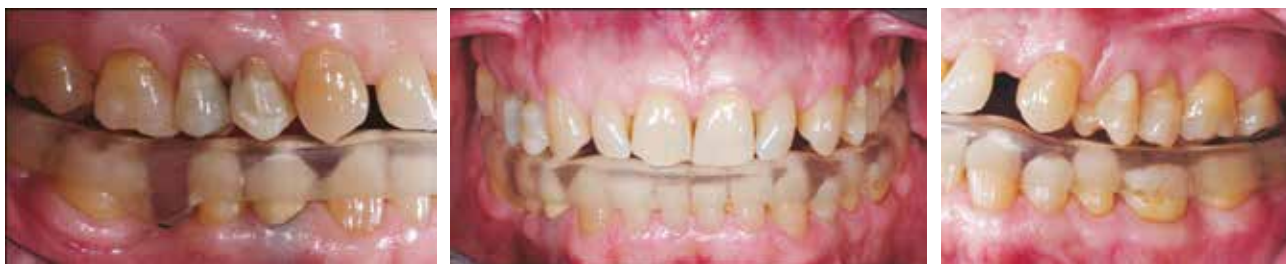

FIG. 6 Intraoral pictures of the splint immediately after delivery.



an occlusal splint with a complete digital approach. After centric relation was recorded with bimanual manipulation, the technique included intraoral scans of the maxillary and mandibular arches, digital registration of vertical relationship, computer-aided design of the intraoral occlusal splint and then manufactured with a multi-jet 3D printer. The presented technique allows for time efficient laboratory manufacturing, which could also be performed chair-side in the dental office. The delivered splint is accurate and precise and could be reproduced anytime if needed.

### Acknowledgments

The authors are grateful to Francesco Grieco and Gaetano Frascina for the precious help.

### REFERENCES

1. Dao TT, Lavigne GJ, Charbonneau A, Feine JS, Lund JP. The efficacy of oral splints in the treatment of myofascial pain of the jaw muscles: a controlled clinical trial. *Pain* 1994;56:85–94.
2. List T, Axelsson S. Management of TMD: evidence from systematic reviews and meta-analyses. *J Oral Rehabil* 2010;37:430–451.
3. Ash MM Jr, Ramfjord SP. Reflections on the Michigan splint and other intraocclusal devices. *J Mich Dent Assoc* 1998;80:32–35,41–46.
4. Ekberg EC, Vallon D, Nilner M. Occlusal appliance therapy in patients with temporomandibular disorders. A double-blind controlled study in a short-term perspective. *Acta Odontol Scand* 1998;56:122–128.
5. Dylina TJ. A Common-Sense Approach to Splint Therapy. *J Prosthet Dent* 2001;86:539–45.
6. Goiato MC, Santos MR, Pesqueira AA, Moreno A, Dos Santos DH, Haddad MF. Prototyping for surgical and prosthetic treatment. *J Craniofac Surg* 2011;22:914–7.
7. Al Mortadi N, Eggbeer D, Lewis J, Williams RJ. CAD/CAM/AM applications in the manufacture of dental appliances. *Am J Orthod Dentofacial Orthop* 2012;142:727–33.
8. Al Mortadi N, Lewis J, Eggbeer D, Williams RJ. Design and fabrication of a sleep apnea device using computer-aided design/additive manufacture technologies. *Proc Inst Mech Eng H* 2013;227:350–5.
9. Grauer D, Wiechmann D, Heymann GC, Swift EJ Jr. Computer-aided design/computer-aided manufacturing technology in customized orthodontic appliances. *J Esthet Restor Dent* 2012;24:3–9.
10. Dedem P, Türp JC. Digital Michigan splint - from intraoral scanning to plasterless manufacturing. *Int J Comput Dent* 2016;19(1):63–76.
11. Venezia P, Torsello F, D'Amato S, Cavalcanti R. Digital cross-mounting: A new opportunity in prosthetic dentistry. *Quintessence Int.* 2017;48:701–709.
12. Dawson PE, *Functional Occlusion from TMJ to Smile Design*. St. Louis: Mosby Elsevier; 2007. p. 74–83.
13. Ender A, Mehl A. Influence of scanning strategies on the accuracy of digital intraoral scanning systems. *Int J Comput Dent* 2013;16:11–21.
14. Ender A, Mehl A. Full arch scans: conventional versus digital impressions – an in-vitro study. *Int J Comput Dent* 2011;14:11–21.
15. Lim JH, Park JM, Kim M, Heo SJ, Myung JY. Comparison of digital intraoral scanner reproducibility and image trueness considering repetitive experience. *J Prosthet Dent*. 2017 Jul 7. pii: S0022-3913(17)30350-5.
16. Marghalani A, Weber HP, Finkelman M, Kudara Y, El Rafie K, Papaspyridakos P. Digital versus conventional implant impressions for partially edentulous arches: An evaluation of accuracy. *J Prosthet Dent* 2017 Sep 16. pii: S0022-3913(17)30492-4.
17. Imburgia M, Logozzo S, Hauschild U, Veronesi G, Mangano C, Mangano FG. Accuracy of four intraoral scanners in oral implantology: a comparative in vitro study. *BMC Oral Health* 2017 Jun 2;17(1):92.
18. Camardella LT, Vilella OV, van Hezel MM, Breuning KH. Accuracy of stereolithographically printed digital models compared to plaster models. *J Orofac Orthop*. 2017 Mar 30.
19. Camardella LT, de Vasconcellos Vilella O, Breuning H. Accuracy of printed dental models made with 2 prototype technologies and different designs of model bases. *Am J Orthod Dentofacial Orthop* 2017;151(6):1178–1187.
20. Lauren M, McIntyre F. A new computer-assisted method for design and fabrication of occlusal splints. *Am J Orthod Dentofacial Orthop* 2008 Apr;133(4Suppl):S130–5.
21. Lauren M, McIntyre F. Digital occlusal splints. *Dent Today* 2008;27(2):150, 152, 154–5.
22. Warunek SP, Lauren M. Computer-based fabrication of occlusal splints for treatment of bruxism and TMD. *J Clin Orthod* 2008;42:227–32.
23. Joda T, Ferrari M. Chairside protocol for posterior single-unit implant restorations in a complete digital workflow. *J Osseointegr* 2018;10(2):33–36.
24. Doldo T, Di Vece L, Ferrari Cagidiaco E, Nuti N, Parrini S, Carboncini F, Ferrari M. A new generation of orthodontic retainer using 3d printing technology: report of two cases. *J Osseointegr* 2018;10(4):142–148.