



Pietro Venezia

Digital cross-mounting: A new opportunity in prosthetic dentistry

Pietro Venezia, DDS¹/Ferruccio Torsello, DDS, PhD²/Salvatore D'Amato, MD, DDS³/Raffaele Cavalcanti, DDS, PhD¹

The prosthodontic management of complex rehabilitations requires several stages of treatment including one or more provisional restorations. The design and adjustments of the provisional are made to achieve an optimal functional and esthetic outcome for the patient. However, the adjustments needed are both time and cost consuming. Therefore, once a

satisfactory provisional is made, the information should not be lost during the following stages of treatment. The purpose of this clinical case is to illustrate “digital cross-mounting,” a procedure used to precisely transfer information from the provisional to the final fixed rehabilitation in a digital workflow. (doi: 10.3290/j.qi.a38863)

Key words: cross-mounting, digital workflow, full-arch rehabilitation, intraoral scanner, monolithic zirconia

The rehabilitation of one or two completely edentulous arches is complex and requires an interdisciplinary team approach combining the proficiency of the prosthodontist, the periodontist, the oral surgeon, and the dental technician. The concept of prosthetically guided rehabilitation is universally recognized: the position of the prosthesis should be the guide for the periodontal and implant surgery.¹

When planning the rehabilitation for a full-arch restoration, several parameters should be taken into consideration in order to achieve a functional prosthesis with an esthetically pleasant result. These include the

craniomandibular relationship with the determination of centric relation position with an adequate vertical dimension, the orientation of the occlusal plane three dimensionally, the occlusal relationship, the perioral tissue support, the tooth display, and the phonetics.²⁻⁹

In the daily routine, the clinician records the aforementioned functional and esthetic parameters. With the diagnostic information, the dental technician fabricates the wax-up and the provisional restoration. The casts should be mounted on the articulator in centric relation at the correct vertical dimension with the aid of a facebow registration. Once the provisional restoration is produced, it is used not only to provide the patient with interim prosthesis, but also to test the function and esthetic changes, as this restoration could be modified for improvement several times in a relatively easy manner.

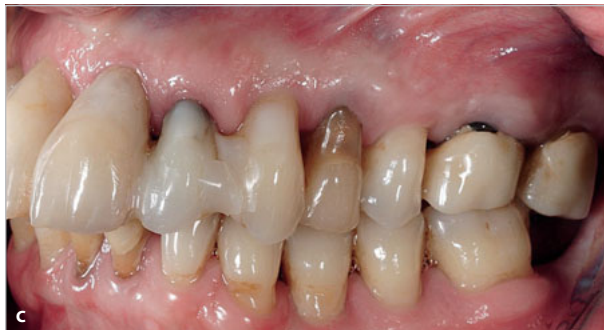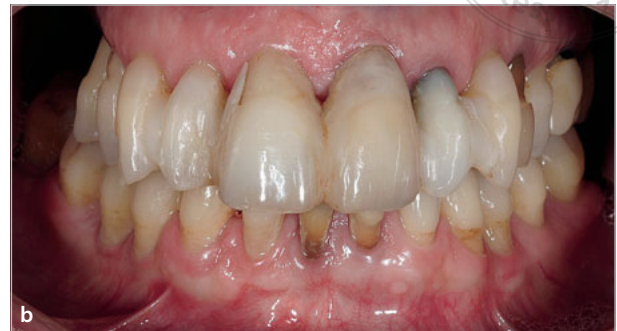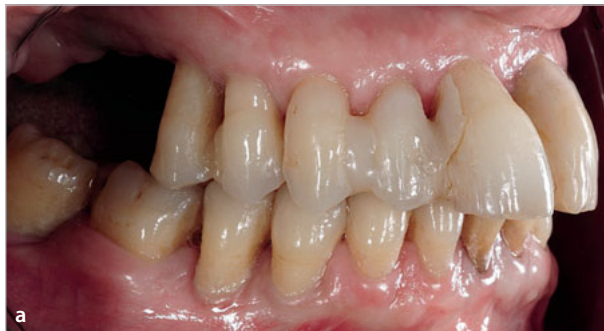After a proper period of time with a functional and esthetic provisional restoration, the definitive prosthesis can be fabricated. The final prosthesis should be identical to the provisional, but with a more durable

¹ Private Practice, Bari, Italy.

² Research Fellow, Department of Periodontics and Prosthodontics, Eastman Dental Hospital, Rome, Italy.

³ Aggregate Professor, Multidisciplinary Department of Medicine and Dentistry, Unit of Maxillo-Facial Surgery, University of Campania “Luigi Vanvitelli”, Naples, Italy.

Correspondence: Dr Pietro Venezia, Studio di Odontoiatria Specialistica “Cavalcanti & Venezia”, Via G. Posca, 15 Bari (BA), 70124, Italy. Email: pierovenetia@gmail.com



Figs 1a to 1c Initial intraoral photographs.

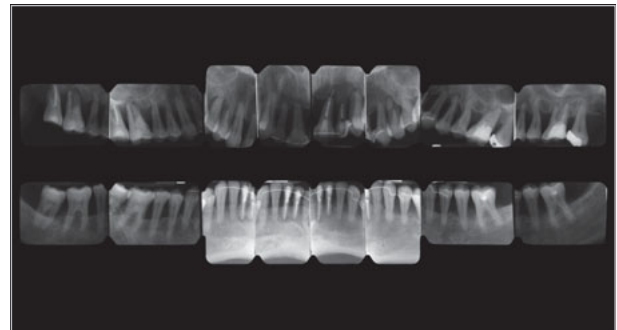


Fig 2 Initial radiographic status.

material. The transition from the temporary to the definitive prosthesis is complex, as it is difficult to reproduce exactly the details of the provisional restoration.

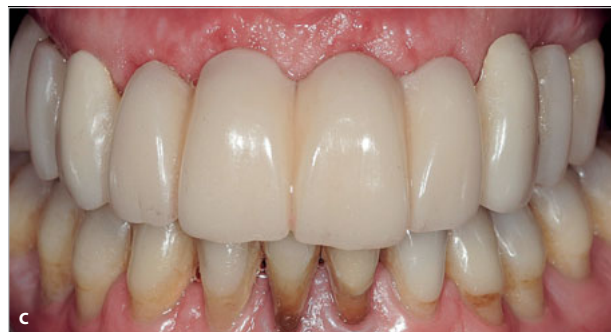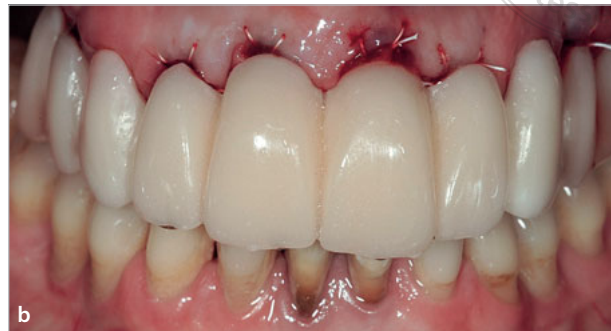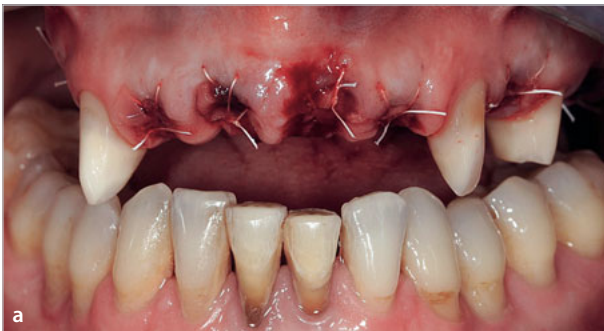Some techniques have been proposed to transfer all the prosthetic information (vertical dimension, centric relation, frontal and lateral guidance, esthetics) in cases treated with a fixed provisional prosthesis supported either by teeth or by implants.^{10,11} Another technique has been proposed for cases in which the provisional and diagnostic phase is performed with a removable denture.¹²

The aim of this article, illustrated through a clinical case, is to integrate a fully digital workflow to accurately transfer diagnostic information from the provisional stage to the definitive fixed prosthesis for a full-arch implant-supported rehabilitation.

CASE REPORT

The patient, a 51-year-old woman, presented with severe attachment loss, multiple sites with acute infection, and mobility in the maxillary arch (Figs 1 and 2).

The periodontal chart was completed and a set of periapical radiographs was performed in order to determine the prognosis of the teeth in the maxilla and in the mandible. Preliminary impressions were taken with irreversible hydrocolloid (Blueprint Xcreme, Dentsply DeTrey). The diagnostic casts were articulated on a semi-adjustable articulator with the aid of a facebow registration and centric relation wax index. Facial and dentolabial analyses were carried out as well as phonetic tests. After this careful examination it was decided that all the remaining teeth in the maxillary arch should be extracted. Several treatment options were reviewed with the patient, and a full-arch implant-supported fixed restoration was selected as the most appropriate for the patient's needs and expectations. With regards to the timing of extractions and implants, immediate placement was excluded because of the presence of acute infections. As the patient desired avoidance of any removable appliance in the provisional phase, a "staged approach" was followed, temporarily maintaining a few teeth in order to support a provisional fixed restoration.¹³



Figs 3a to 3c Anterior photographs taken immediately after tooth extractions and socket preservation procedures, at the moment of delivery of the first provisional restoration and after the healing period.

A prescription with precise indications regarding the vertical dimension, the position of the new incisal edge, and the desired occlusal scheme was sent to the dental laboratory technician, who produced a wax-up of the prosthetic project.

It was decided to maintain three teeth in strategic positions (the maxillary right and left canines and left second premolar) as abutments for a fixed provisional restoration of polymethyl methacrylate (PMMA) with a metal reinforcement that was manufactured by the technician with an analogic workflow before tooth extractions. The maxillary right and left canines and left second premolar were endodontically treated.

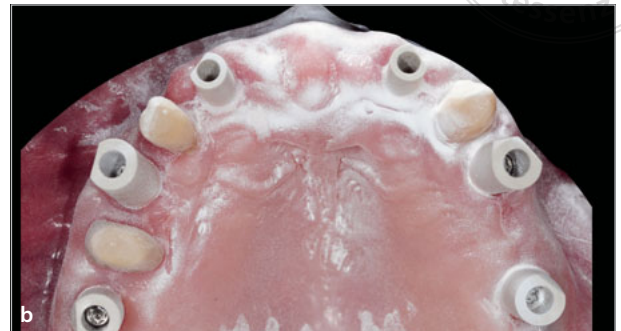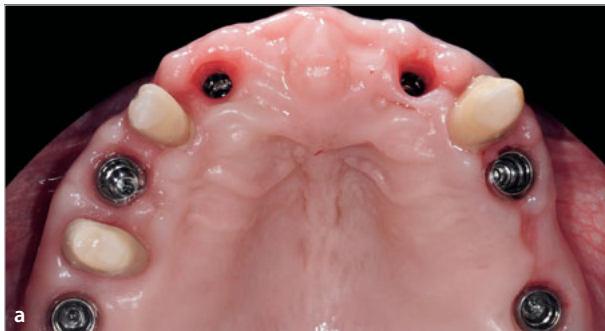In one single clinical session, all teeth with the exception of the maxillary right and left canines and left second premolar were extracted and socket preservation procedures were performed with a mix of inorganic bovine bone and porcine collagen (Bio-Oss Collagen, Geistlich Pharma). In the same session, the natural abutments in the positions of the maxillary right and left canines and left second premolar were prepared and the provisional restoration was relined, refined,

and cemented. The patient was checked 10 days later for suture removal and for a control of her oral situation (Fig 3). Thereafter, the healing of soft and hard tissues was controlled every 6 weeks.

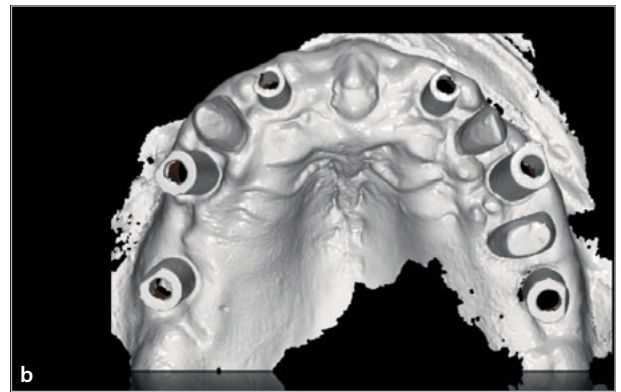
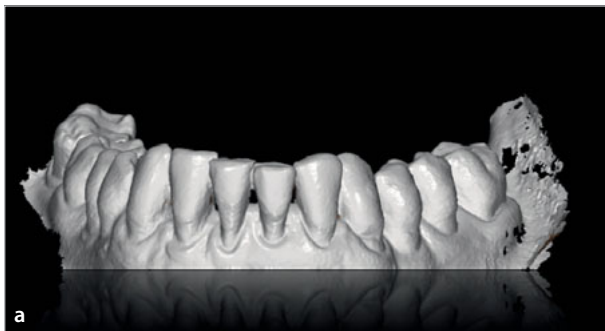Seven months after tooth extractions, six implants were placed with the aid of a surgical template: two Bone Level Tapered implants (Straumann) in the maxillary lateral incisor positions (diameter 3.3 mm) and four Soft Tissue Level implants (Straumann) in the maxillary first premolar positions (diameter 3.3 mm) and in the maxillary first molar positions (diameter 4.1 mm). All the implants presented with a sand-blasted, acid-etched, chemically activated surface (SLActive, Straumann).

The use of a metal-reinforced provisional on natural abutments allowed undisturbed healing of the implants and provided the patient with a fixed restoration for the whole duration of the treatment.

After an osseointegration period of 8 weeks, the implants were visually inspected and hand-checked and were considered ready to support the loading.¹⁴⁻¹⁶ From this moment a totally digital workflow was used.



Figs 4a and 4b Occlusal photographs of natural abutments and healed implants with scan bodies in situ and opacizing powder used to accelerate the scan.



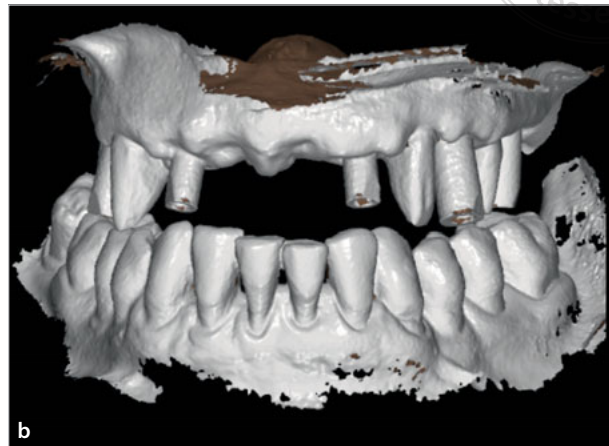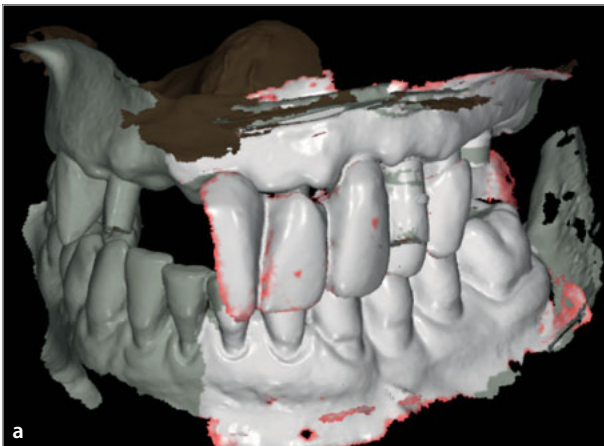
Figs 5a and 5b Digital impressions of the maxillary and mandibular arches before intermaxillary registration.

The temporary prosthesis and the healing abutment were removed, the Scan Bodies provided by the manufacturer for intraoral scan (Scan Body, Straumann) were secured to the implants, and the digital implant impression of the maxillary arch was taken (Fig 4). This acquisition provided the information regarding the position and the morphology of implants and remaining teeth, as well as periodontal and peri-implant tissues. The digital impression was widely extended towards the palate to record the rugae palatine and the incisal papilla and towards the vestibule to include not only the teeth but also the surrounding structures (Fig 5).¹⁷ The scanner used for this clinical case (True Definition Scan, 3M Espe) operates with contrast patterning powder to increase the speed of the impression, to facilitate the data acquisition, and to improve its accuracy.

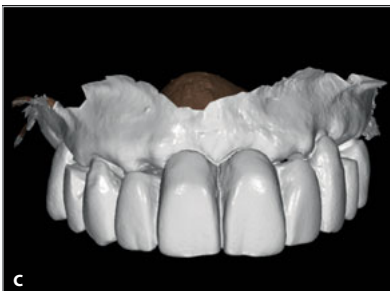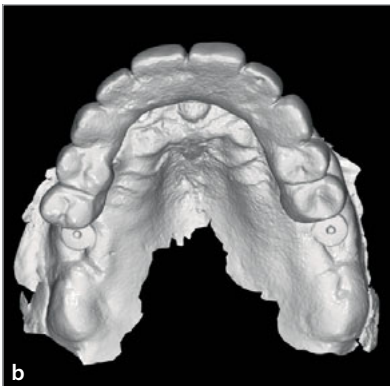
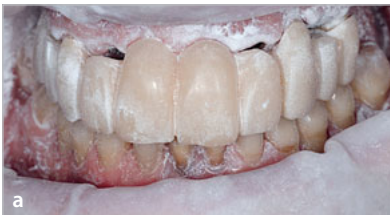The digital impression of the mandibular arch was then acquired in a second scan (Fig 5).

The scan bodies in the maxillary arch were removed, the provisional prosthesis repositioned, and a third acquisition was performed on the vestibular side with the provisional prosthesis in situ with maxillary and mandibular arches in contact. This acquisition allowed for the bite registration between the maxillary and mandibular scans: in the bite registration function, the software was designed to take into consideration only the landmarks needed for this purpose. The care taken in the previous scans to extend the acquisition to the soft tissues allowed recording of enough points in common with the bite registrations. Consequently the maxillary and mandibular arches were “digitally mounted” with the correct intermaxillary relations (Fig 6). This procedure could be named “digital cross-mounting” as it replicates the process of analog cross-mounting (Fig 6).

A fourth impression (auxiliary scan) of the maxillary arch with the provisional prosthesis in situ was taken.



Figs 6a and 6b Bite registration using the provisional restoration. This registration allows mounting of the maxillary and mandibular digital impressions in the correct relation.

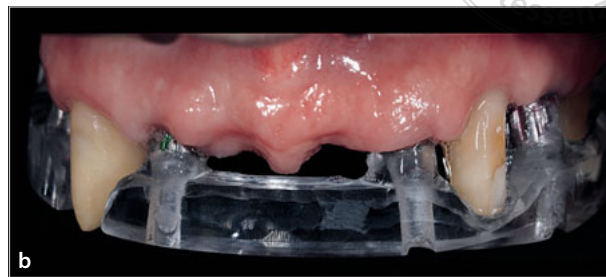
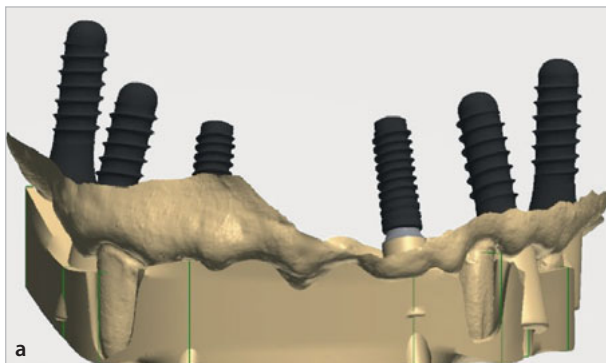


Figs 7a to 7c Digital impression of the maxillary arch with the provisional prosthesis.

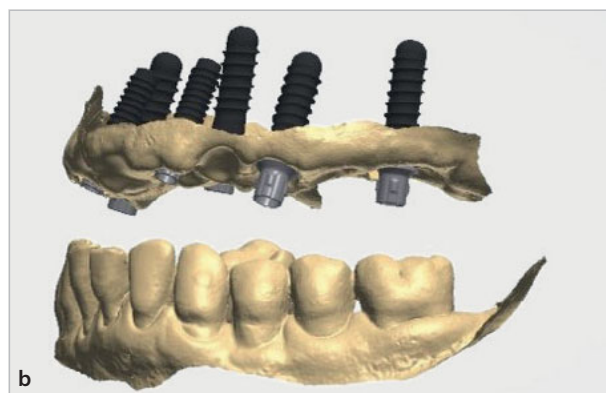
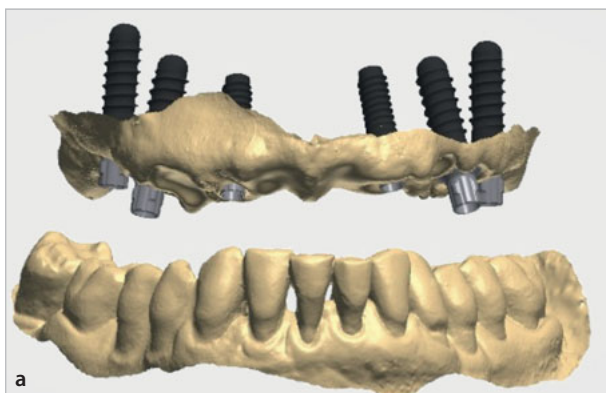
Once again, care was taken to extend the acquisition to the surrounding structures (rugae palatine, periodontal structures) that provide the references to superimpose the different digital impressions. The aim of the auxiliary scan was to provide the dental laboratory technician with information regarding the functionalized provisional prosthesis, such as the incisal edge position, the occlusal plane, the incisal and canine guidance, the occlusal contacts, and the width and length of the teeth (Fig 7).

Once the intermaxillary relation was established in the planning software, the abutments were chosen from the software library (Variobase abutments, Straumann).

Before proceeding, the accuracy of the scanned implant position was tested: a resin jig was designed with the software, milled, luted on the abutments, and tried intraorally (Fig 8). Since good fit and precision were found both clinically and radiographically, the digital impression was accurate and the process of fabricating a new, implant-supported provisional was started. The remaining natural abutments (the maxillary right and left canines and left second premolar) were “virtually” extracted and the provisional restoration was designed on the basis of the information regarding the shapes and volumes of the tooth-supported provisional that was previously scanned (Figs 9 and 10). Ovate pontics were designed at the planned extraction sites to guide soft tissue healing and condi-



Figs 8a and 8b Design and try-in of the verifying jig.



Figs 9a and 9b The maxillary and mandibular digital impressions in the correct intermaxillary relations after the digital cross-mounting procedure in the dental technician software. Natural abutments have been “virtually” extracted and Variobase abutments placed on implants.

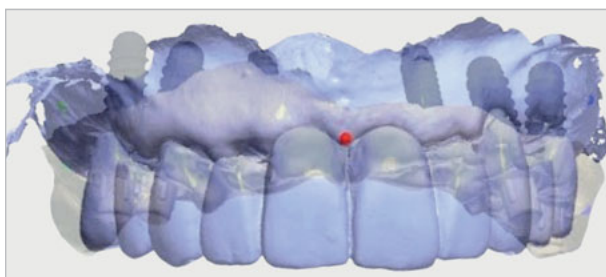
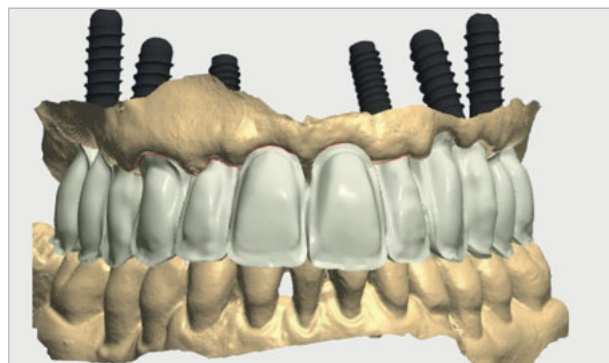
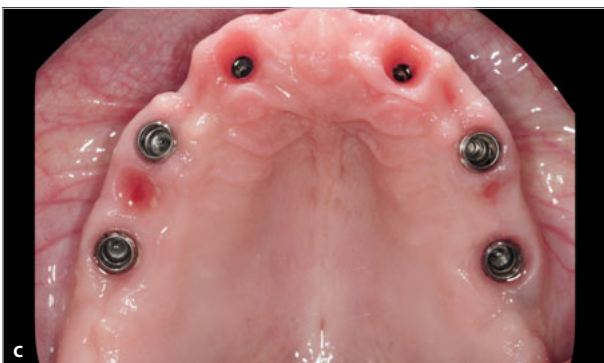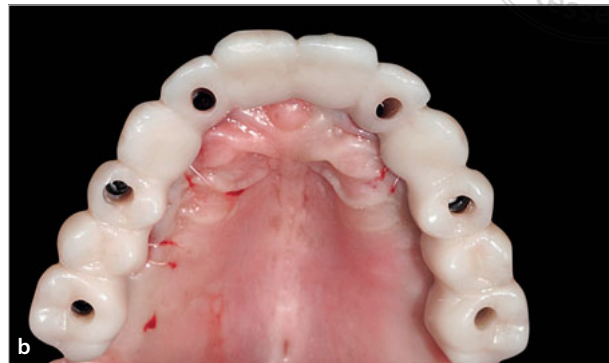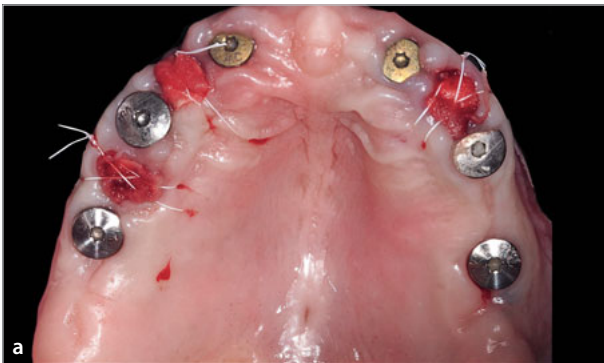


Fig 10 Superimposition of the digital impressions of the implants and of the provisional restoration.

tioning.^{18,19} Canine and incisal guidance were checked with the “digital articulator” function of the software. The project was then realized by milling a PMMA block, the new provisional was luted to the Variobase abutments and sent to the dental clinic. The three remaining natural abutments were removed and socket preservation procedures were performed to maintain bone volume at the pontic sites. A few minutes after the sur-

gical session, the screw-retained provisional was delivered to the patient: it demonstrated excellent fit and precision and only minor occlusal adjustments were needed (Fig 11).

The implant-supported provisional prosthesis was kept for 7 months for complete healing at the extraction sites and complete soft tissue conditioning (Fig 11). This period was also useful to test once again the prosthetic project. Since no damage (chipping or fracture) to the resin was found and no screw loosening recorded, the project was considered appropriate and it was decided to replicate it in a more durable material. A new digital impression of the implant-supported provisional was taken to record the soft tissues around the implants and the ovate pontic areas and to visualize eventual occlusal wear. This impression was matched with the virtual “master model” and the implant analogs (Fig 12).



Figs 11a to 11c Occlusal views of the maxillary arch (a) immediately after tooth extraction, (b) after the delivery of the monolithic PMMA implant supported provisional restoration (same day), and (c) after 7 months of healing.

Fig 12 Digital project of the final restoration.

A definitive screw-retained rehabilitation in monolithic zirconia with porcelain veneering limited to the labial surface was manufactured.²⁰ A virtual cut-back of the vestibular surface from the digital impression of the provisional was performed to allow porcelain stratification. Occlusal and palatal surfaces were left unmodified, since no veneering was to be performed. The zirconia framework was milled with an occlusal surface identical to the provisional after 7 months of use and tried-in to verify the fit and occlusal contacts according to a mutually protected occlusal scheme (Fig 13).

Maxillary and mandibular resin casts were produced with a three-dimensional (3D) printing machine based on STL-files (Dreve Dentamid) to position the zirconia framework and to facilitate the veneering of feldspathic porcelain.

The occlusal and palatal areas were infiltrated with colors optimized for zirconia, and the vestibular aspect

was veneered with porcelain (E-max Ceram, Ivoclar Vivadent). The prosthesis was cemented to the titanium abutments with resin cement (Panavia F, Kuraray) and delivered to the patient (Fig 14).

DISCUSSION AND CONCLUSION

Complex rehabilitations require a considerable amount of time and effort in treatment planning, and several stages of treatment with one or more provisional restorations.

The possibility to keep the information during the transition from the provisional to the final restorations has been analyzed in previous papers. The cross-mounting technique, as described by Calesini et al¹¹ in 1996, allows a perfect interchange of the casts, replicating the provisional restoration with the mastercasts of both arches.¹¹ All the combinations of the four casts (two of

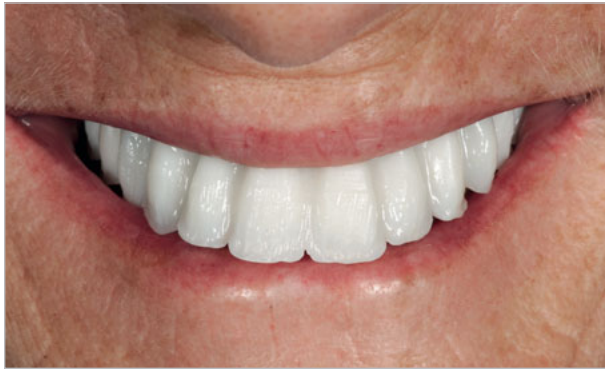

Fig 13 Zirconia framework try in. The framework is obtained by a digital duplicate of the provisional and a virtual cut-back of the vestibular surfaces.

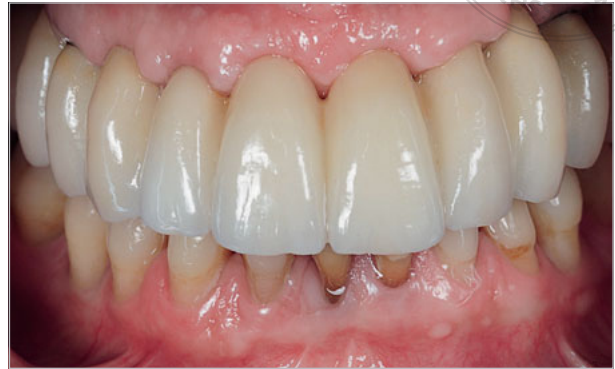

Fig 14 Intraoral view of the final rehabilitation in place.

the provisional arches and two mastercasts) could be mounted on the same articulator at the same vertical dimension and with the same 3D spatial relationships. In the same articulator, with the aid of silicon indexes recorded on the provisional casts, it is also possible to combine the information regarding the final restorations with the mastercasts.

New technology, such as digital impressions and computer-aided design/computer-assisted manufacture (CAD/CAM), has improved the production of prosthetic devices in prosthodontics. The possibility to have precise reproductions of dental arches is not sufficient in cases when intermaxillary relation is difficult to record. This is the case when one or both arches are edentulous. The authors developed a protocol to record the intermaxillary relation in a digital manner to have a fully digital workflow. The protocol was inspired by the "cross-mounting" procedure that was used for several years by the authors, but modified to be used with digital technology, which simplified the process for the clinician and the dental technician.

The software acquires the impressions of the edentulous arch and the opposing arch, and records the correct relation through the scan of the buccal aspect in occlusion with the provisional restoration in situ. After the superimposition, the bite registration with the provisional is removed in the software and the result is the visualization of the two arches in the correct inter-

maxillary relation. Furthermore, the software overlaps the provisional prosthesis to verify the functional and esthetic information, such as incisal edge position, incisal guidance, tooth volumes, and posterior occlusal contacts. This results in an easier design of the final rehabilitation that is identical to the provisional.

A consequence of this approach is to emphasize the importance of the provisional phase, which is, in the authors' opinion, part of the diagnostic phase. For this reason great care is taken to provide the patient with a temporary restoration that should be esthetically and functionally adequate. Several adjustments should be made and kept in the mouth and tested for a reasonable period of time. The design of the provisional and adjustments made to adapt it to patient's function and esthetics are time consuming; thus, once an adequate and pleasing result is achieved, the information gained should not be lost during the rest of the treatment: the final rehabilitation should be identical to the temporary prosthesis in a more durable material.

ACKNOWLEDGMENTS

The authors thank Dr Catherine DeFuria for her language review. The authors thank Pasquale Lacasella and Francesco Grieco for their help in the laboratory procedures.



REFERENCES

1. Israelson H, Plemons JM, Watkins P, Sory C. Barium-coated surgical stents and computer-assisted tomography in the preoperative assessment of dental implant patients. *Int J Periodontics Restorative Dent* 1992;12:52–61.
2. Silverman MM. Accurate measurement of vertical dimension by phonetics and the closest speaking centric space. Part I. *Dent Digest* 1951;57:261–265.
3. Pound E. Cross arch splinting vs. premature extractions. *J Prosthet Dent* 1966;16:1058–1068.
4. Pound E. Let /S/ be your guide. *J Prosthet Dent* 1977;38:482–489.
5. Rivera-Morales WC, Mohl ND. Variability of closest speaking space compared with interocclusal distance in dentulous subjects. *J Prosthet Dent* 1991;65:228–232.
6. Rivera-Morales WC, Mohl ND. Relationship of occlusal vertical dimension to the health of the masticatory system. *J Prosthet Dent* 1991;65:547–553.
7. Gross MD, Ormianer Z. A preliminary study on the effect of occlusal vertical dimension increase on mandibular postural rest position. *Int J Prosthodont* 1994;7:216–226.
8. Fradeani M. Phonetic Analysis: Appraising the dentolabial relationship during phonesis to determine ideal incisal length, adequate tooth position and correct vertical dimension of occlusion. In: Fradeani M. *Esthetic rehabilitation in fixed prosthodontics, Vol 1: Esthetic analysis*. Chicago: Quintessence Publishing, 2004.
9. Zitzmann NU, Marinello CP. Treatment plan for restoring the edentulous maxilla with implant-supported restorations: removable overdenture versus fixed partial denture design. *J Prosthet Dent* 1999;82:188–196.
10. Biscaro L, Becatelli A, Poggio PM, Soattin M, Rossini F. The One-Model Technique: a new method for immediate loading with fixed prostheses in edentulous or potentially edentulous jaws. *Int J Periodontics Restorative Dent* 2009;29:306–313.
11. Calesini G, Bruschi GB, Scipioni A, Micarelli C. Il montaggio crociato in protesi ancorata ad impianti osteointegrati. *Quintessence Int* 1996;8/9:435.
12. Venezia P, Lacasella P, Cordaro L, Torsello F, Cavalcanti R. The BARI technique: a new approach to immediate loading. *Int J Esthet Dent* 2015;10:428–443.
13. Cordaro L, Torsello F, Ercoli C, Gallucci G. Transition from failing dentition to a fixed implant-supported restoration: a staged approach. *Int J Periodontics Restorative Dent* 2007;27:481–487.
14. Cochran DL, Jackson JM, Bernard JP, et al. A 5-year prospective multicenter study of early loaded titanium implants with a sandblasted and acid-etched surface. *Int J Oral Maxillofac Implants* 2011;26:1324–1332.
15. Buser D, Janner SF, Wittneben JG, Brägger U, Ramseier CA, Salvi GE. 10-year survival and success rates of 511 titanium implants with a sandblasted and acid-etched surface: a retrospective study in 303 partially edentulous patients. *Clin Implant Dent Relat Res* 2012;14:839–851.
16. Bornstein MM, Wittneben JG, Brägger U, Buser D. Early loading at 21 days of non-submerged titanium implants with a chemically modified sandblasted and acid-etched surface: 3-year results of a prospective study in the posterior mandible. *J Periodontol* 2010;81:809–818.
17. Kattadiyil MT, Mursic Z, AlRumaih H, Goodacre CJ. Intraoral scanning of hard and soft tissues for partial removable dental prosthesis fabrication. *J Prosthet Dent* 2014;112:444–448.
18. Kinsel RP, Lamb RE. Development of gingival esthetics in the terminal dentition patient prior to dental implant placement using a full-arch transitional fixed prosthesis: a case report. *Int J Oral Maxillofac Implants* 2001;16:583–589.
19. Cordaro L, Torsello F. Soft tissue conditioning by immediate restoration of immediately placed implants in full-arch rehabilitation: the double provisional technique. *Eur J Esthet Dent* 2006;1:216–229.
20. Venezia P, Torsello F, Cavalcanti R, D'Amato S. Retrospective analysis of 26 complete-arch implant-supported monolithic zirconia prostheses with feldspathic porcelain veneering limited to the facial surface. *J Prosthet Dent* 2015;114:506–512.